

---

## Shoulder injuries in dogs

Lameness caused by damage to the shoulder in dogs is not an unusual presentation but making the diagnosis can be very difficult. Most dogs that injure their shoulders are larger breed dogs or dogs competing at agility or “fly ball” or high level working dogs. The injury usually occurs as a result of repeated stress rather than a single episode and the lameness can be intermittent in nature.

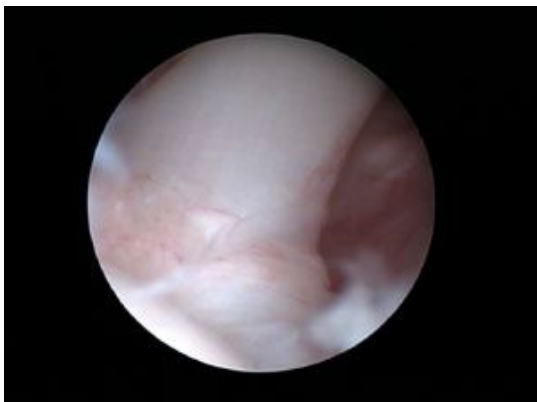### Making the diagnosis

This can be extremely challenging especially if the lameness is only occasionally. Because the patients are usually middle aged larger breed dogs ruling out elbow problems is also very important. Because the injury is usually to a ligament or tendon there may be no changes visible on an X ray. We use careful assessment and palpation conscious and under anaesthesia, ultrasound examination, x rays and arthroscopy to make the diagnosis and on some occasions we may also advise arthroscopy of the elbow to rule out pathology here as a confusing factor. We usually like to take x rays and perform the ultrasound examination on one day under anaesthesia and then talk to you about those findings before we proceed to arthroscopy.

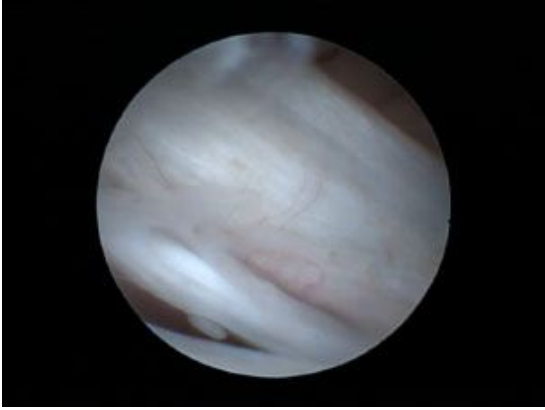
### The complex nature of the shoulder

The shoulder joint is a bit like a football sitting on a saucer and is intrinsically quite unstable. Because of this there are a number of ligaments and tendons and muscles that work together in and around the shoulder to provide it with the necessary stability to give the dog its function. The cause of lameness can come from any one or more of these structures and treatment may involve physiotherapy and pain killers, injection of drugs into the joint, injection of the dog's own treated blood into damaged muscles, the use of the dog's own stem cells or surgery to replace a damaged ligament or release a damaged tendon. Precisely which treatment depends very much on what is damaged.

In most cases an arthroscopy is performed to achieve a diagnosis, a simple procedure such as releasing a damaged ligament or removing a chip fracture may be indicated in which case we proceed under the same anaesthetic as the arthroscopy. In more complex cases the specific treatment may involve reconstruction of ligaments or injection of stem cells into damaged muscles. In these cases the treatment will be booked in for another date so that we can liaise with the stem cell lab or arrange for fitting for a supporting brace prior to surgery.



Arthroscopic picture of a  
biceps tendon



Arthroscopic picture of a  
torn medial glenohumeral ligament

The following list gives an indication to how specific injuries may be treated:

- Ruptured Medial Glenohumeral Ligament and or torn Subscapularis. This is one of the most common causes of lameness in the shoulder and 85% of cases will return to normal with specific physiotherapy and use of a custom shoulder support. For those cases that do not recover or the damage is extensive or the dog is required for active work such as agility, fly ball or field trials reconstructive surgery will usually resolve the lameness. The reconstructive surgery would be performed after the dog has been fitted for a shoulder brace to protect the repair.
- Isolated damage to the biceps tendon. This can occur as a result of minor trauma. If the majority of the tendon is still intact then we usually try and heal the tendon with specific physiotherapy and or intra articular injections of drugs. In more advanced cases or where the injured tendon will not heal then tenotomy or release of the tendon can be performed arthroscopically. Stem cell treatments may be beneficial in these cases.
- Damage to the Lateral Glenohumeral Ligament and or capsule. This is an uncommon cause of lameness but cases rarely resolve without restablising surgery. The stabilising surgery is performed at another date once the dog has been fitted for a shoulder support brace which is required to support the repair.
- Supraspinatus insertionopathy. This is a relatively common injury and involves injury and failure to heal of the supraspinatus muscle. It may have similarities to rotator cuff injuries in people. The condition may also have secondary implications with impingement of the biceps tendon and damage to the biceps tendon must be treated concurrently. In most simple cases we will treat the primary injury with injection of the dog's own blood that has been treated in a specific way to harvest the growth factors, however in advanced cases or where there is significant damage to the biceps tendon we need to release the biceps tendon and or use stem cell treatments to stimulate supraspinatus healing.
- Stem cell treatments use the dog's own stem cells harvested from fat within the abdomen to encourage healing. It involves a small abdominal surgery to remove some fat which is sent to the stem cell lab where the cells are isolated and grown. The stem cells are then sent back about 2 weeks later to be re injected into the damaged tissue. The fat harvest procedure is performed after liasing with the stem cell lab and is not normally performed the same day as the arthroscopy.