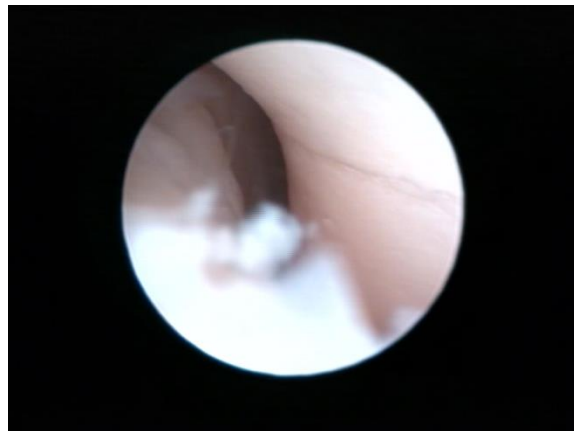
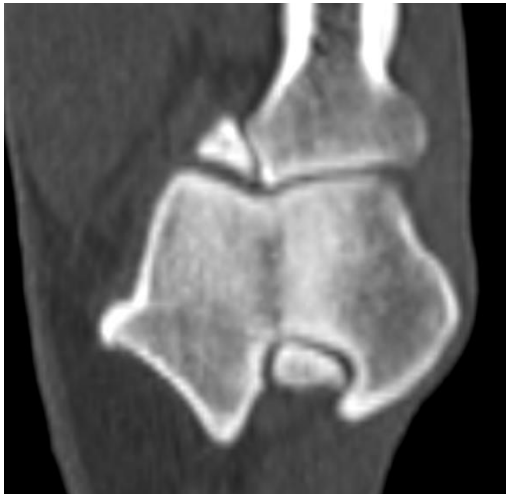

## Stress fracture of the Humeral Condyle

This is a rare condition seen almost exclusively in Spaniels, the exact cause is unclear but the result is a hairline defect in the end of the humerus (the condyle) that ends into the joint surface. Some have speculated that it may be caused by failure of a zone of cartilage to become bone as the dog is growing, others have suggested that it may be a stress fracture caused by abnormal forces within the elbow joint. The defect may cause pain because joint fluid starts to seep into the bone or it may cause pain because the end of the humerus is starting to be forced apart and in some cases it can lead to a full fracture of the end of the humerus involving the elbow joint.

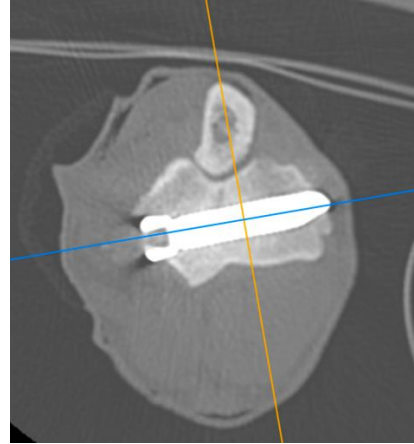
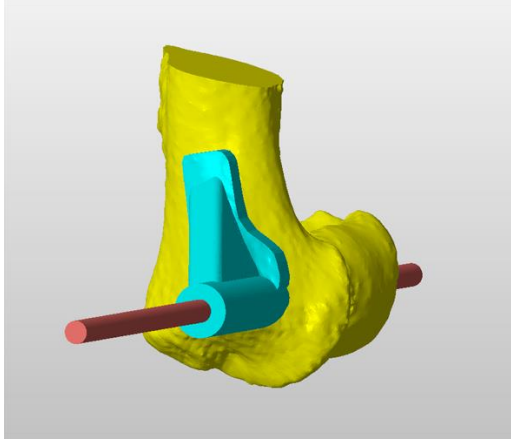
### Investigations:

- In some cases simple plain radiographs (X rays) can show the defect.
- Arthroscopy can clearly show the defect extending into the joint surface
- Computed Tomography (CT) is the gold standard way to diagnose the condition



### Surgical Treatment

No one procedure has been shown to be better than another and so we use a technique to place as big a screw as possible across the humerus, typically a 5mm screw made of Titanium. In order to place this as accurately as possible we have a Computer Aided Design custom drill guide made from the CT data. This does not completely eliminate risk but it does reduce the risk. The results so far (as of April 2020) have shown this technique to be safe and reliable with a low rate of infection and other major complication.



All cases will have a dressing of for a minimum of 7 days and in some cases we may extend this to two weeks. We will always remove or replace the dressing after 7 days, this should be performed under sedation.

After surgery your dog must be kept rested and quiet, this can only be achieved properly with cage confinement for 2 weeks followed by house confinement for another 2 to 4 weeks, having lead toilet exercise only (50 to 100yd lead walk four times a day). Pain killers and antibiotics are mandatory and a Buster Collar must be worn until the stitches are removed 14 days after surgery.

There are some risks with this including infection, fractures and nerve damage and although the guide significantly increase accuracy it doesn't eliminate all risks. In order to use the guides we sometimes have to take down some of the medial collateral ligament, in these cases patients need to be cage confined for 4 weeks post op and these cases will have a dressing on for two weeks.

We usually check on cases after 6 weeks (at the end of their strict confinement) before we start to build up lead controlled exercise over another 4 to 6 weeks. We will then see them back after 3 to 4 months for check up CT scans.